

Original Article

Evaluation of Hepatoprotective Effect of Essential Oil of *Etilingera Fenzlii* (Kurz) Skronick & M. Sabu (Zingiberaceae) – The Honey Bee Repellent Endemic Plant Species of Andaman Nicobar Islands

Anju Sudhakaran^{1*}, K.B. Ramesh Kumar² and R.K. Radha¹

¹Biotechnology & Bioinformatics Division and

²Phytochemistry & Phytopharmacology Division,

Jawaharlal Nehru Tropical Botanic Garden and Research Institute,

Palode, Thiruvananthapuram, Kerala – 695 562, India

Abstract

Background: *Etilingera fenzlii* (Kurz) Skronick & M. Sabu (Zingiberaceae), is an endemic species of the Andaman Nicobar Islands. Used by the nomadic tribes, shompens as honey bee repellent and also used against malaria fever, gastrointestinal disorders, wherein the root and flower is boiled in water and used to wash the uterus after child birth.

Aim: The present study was aimed to investigate the essential oil of *Etilingera fenzlii* (EOEF) in ethanol induced hepatotoxicity in Wistar albino rats and silymarin was used as positive control.

Methods: Standard drug (Silymarin), essential oil, ethanol were administered orally for 28 days. On 28th day animals were sacrificed and blood was collected for assessment of AST, ALT, ALP, total protein, albumin, globulin and histopathological changes in the liver of different groups were also studied.

Results: Oral administration of ethanol significantly increased biochemical parameters such as AST, ALT, ALP levels and whereas reverse was observed with test compounds (Silymarin and essential oil). Histopathological studies further substantiate the hepatoprotective effect of *E.fenzlii* essential oil.

Conclusion: Our observation indicates that essential oil of *E.fenzlii* shows hepatoprotective activity compared to standard drug silymarin. The present study thus provides a scientific rationale for the traditional use of *E.fenzlii* in the management of liver disorders.

*Corresponding author :

Biotechnology & Bioinformatics Division, Jawaharlal Nehru Tropical Botanic Garden and Research Institute, Palode, Thiruvananthapuram, Kerala – 695 562, India; E-mail: anju2pallath@gmail.com

(Received on Aug. 10, 2019)

Introduction

Etilingera fenzlii (Zingiberaceae) is an endemic species in the Andaman Nicobar Islands which is

exclusively used by the local tribe called as Shompens as a bee repellent for honey collection (1). During their honey collection, chew the plant parts of *E.fenzlii* and spit out the sap filled in the mouth as coarse spray on the bee hives which tranquilize the honey bees and protect them from bee stings. The chemical characterization on essential oils of the species carried out by authors proved that *E.fenzlii* has effective repellent or tranquilizing property towards insects (2). The major constituents identified were long chain aliphatic compounds (n-dodecanol, n-undecanol and n-tetradecanol etc.). Use of natural insecticide is growing today because of its safety and efficacy as alternative remedy for synthetic repellent. It is documented that the volatile oils having all these constituents/isolates have proved to be effective eco-friendly and possess varying degrees of insects/pest controlling properties (3). There is a need for further standardized studies in order to better evaluate the repellent compounds and develop new products that offer high repellency as well as good consumer safety because natural insecticides are usually prescribed to be applied for a long period and hence may cause adverse effects including allergic contact dermatitis, photosensitization, neurotoxicity, causing an overall decline in the normal function in liver and carcinogenicity in human beings, thereby warranting evaluation of their efficacy and safety profile(4). Perusal of the acute and dermal toxicity analysis reveals that the essential oil of the plant did not divulge any significant toxicity and was found to be safe up to 2000 mg/kg in *in vivo* concentration (2). Besides this repellent property this plant were traditionally used for the treatment of malarial fever, stomach and gastro intestinal disorders.

The liver, an important organ, performs critical functions such as production of serum proteins and hormones, metabolism of endogenous and exogenous substances, detoxification and so on (5). The main liver functions include the production of energy by protein, carbohydrate and lipid metabolism, the synthesis of bile salts, the storage of vitamins and lipoproteins production. Therefore, hepatic diseases such as fatty liver disease, hepatitis and cirrhosis highly impact the homeostasis of the body (6).

Alcoholic liver disease is a worldwide health problem

which has three manifestations in form of fatty liver/steatosis, alcoholic hepatitis and liver cirrhosis. At least 80% of chronic alcoholic consumers may develop steatosis, 10-35% alcoholic hepatitis and approximately 10% liver cirrhosis. Intake of alcohol causes accumulation of reactive oxygen species (ROS) like superoxide, hydroxyl radical and hydrogen peroxide in the hepatic cells that oxidize the glutathione which leads to lipid peroxidation of cellular membranes, oxidation of protein and DNA resulting in hepatic damage (7). Treatment options are available for common liver diseases such as cirrhosis, fatty liver and chronic hepatitis are inadequate in modern medicine. Conventional drugs used in the treatment of liver diseases such as corticosteroids, antiviral, immunosuppressant may lead to serious adverse effects; they may even cause hepatic damage on prolonged use. Therefore, alternative drugs in the form of herbal medicines which are now used for the treatment of liver diseases are sought instead of currently used drugs (8, 9).

However, there is still no report on the hepatoprotective effect of the essential oil of *E.fenzlii*. Therefore, the present study was an attempt to evaluate the hepatoprotective activity of the essential oil against ethanol induced liver damage in Wistar albino rats.

Materials and Methods

Plant material

Plants were collected from Mount Harriet hill ranges of South Andamans and living plant collections are introduced in to the field gene bank of Jawaharlal Nehru Tropical Botanic Garden and Research Institute (JNTBGRI) campus and a voucher specimen was deposited in the herbarium of the Institute. Fresh leaves were collected, washed under running tap water and were used immediately to extract the essential oil.

Preparation of essential oil of *E.fenzlii*

Fresh leaves (400 g) were hydro distilled for 3 hours using a Clevenger-type apparatus to obtain the essential oil. The oil were collected and dried over

anhydrous sodium sulphate (Na_2SO_4) and stored at 10°C until analysed.

Animals

Wistar albino rats, obtained from College of Veterinary and Animal Science, Mannuthy, Thrissur District were used. They were housed under standard laboratory conditions and were fed commercial rat feed (Manufactured by Sai Durga Feeds and Foods, Bangalore) and boiled water, *ad libitum*. All animal experiments were carried out according to NIH guidelines, after getting the approval of the Institutional Animal Ethics Committee (IAEC) of CARE KERALAM Ltd.

Hepatoprotective activity

Study design

After acclimation for one week, mice were randomly divided into five groups consisting of six animals per group.

Group I (normal control) served as normal and orally given 2 ml distilled water, p.o. once daily for 28 days

Group II (negative control) is given ethanol 40% v/v, 2 ml/100 g, p.o once daily for 28 days.

Group III (positive control) is given silymarin (100 mg/kg, p.o.) and ethanol (40% v/v, 2 ml/100 g, p.o) once daily for 28 days.

Group IV received essential oil at a dose of 5 mg/kg p.o. and ethanol (40% v/v, 2 ml/100 g, p.o) once daily for 28 days. (From the pilot study, low dose (1 and 2 mg/kg) was not found to be effective, so we select higher doses of essential oil).

Group V received essential oil at a dose of 10 mg/kg for a period of 28 consecutive days orally.

After the last treatment, animals were sacrificed by mild ether anaesthesia and all the five groups, blood sample were collected and subjected to the liver

function tests (10). All the procedures carried out on animals were approved by the institutional animal ethics committee.

Biochemical estimations

The blood samples were collected and were centrifuged at 3500 rpm for 15 min to obtain serum. Serum was separated and used for the assay of Aspartate amino transferase (AST), Alanine transaminase (ALT) Alkaline phosphatase (ALP), total protein, Albumin and Bilirubin.

Histopathological studies

After blood draining, liver samples were excised from the control and treated groups of animals and washed with normal saline separately. They were fixed in 10% buffered formalin for 24 h. The formalin-fixed liver samples were stained with haematoxylin–eosin for photomicroscopic observations of the liver histological architecture of each sample were performed.

Statistical analysis

Statistical analysis was carried out Analysis of variance (ANOVA), One way ANOVA followed by Dunnet's test is performed in which the Negative control was compared with all the other groups and the values are expressed in Mean \pm SD.

Results

Biochemical estimations

Effect of AST, ALT and ALP levels in serum

Ethanol treated mice groups produced a significant elevation of ALT, AST and ALP levels in serum compared with normal group, reflecting the tissue damages in liver. Administration of essential oil of *E.fenzlii* (EOEF) and silymarin had obviously reversed this elevation towards normal. Treatment with essential oil caused significant reduction of these values (Table I), dose-dependently, almost comparable to the silymarin treated group.

In the present study, treatment with 40% ethanol (2 ml/100 g) resulted in significantly high levels of AST when compared to the normal control group ($P<0.001$). However, treatment with EOEF (5 mg/kg and 10 mg/kg) and silymarin (100 mg/kg) caused significant normalization of AST ($P<0.01$). Elevated ALT levels were noted in ethanol intoxicated animals ($P<0.001$), whereas in treatment groups, EOEF (5 mg/kg and 10 mg/kg) and silymarin (100 mg/kg) resulted significant reduction of ALT which were comparable to the normal control group (Table I).

Similar to AST and ALT, ALP levels were also found to be elevated ($P<0.001$) in the ethanol (negative) control group in the present study. However, treatment with EOEF (5 mg/kg and 10 mg/kg) and silymarin (100 mg/kg) caused significant reduction in ALT values in the treatment groups. In comparison with control group, there was significant increase in the levels of AST, ALT and ALP in ethanol intoxicated rats, reflecting the liver injury by ethanol. The elevated levels of AST, ALT and ALP were significantly reduced in the animals groups treated with essential oil, almost comparable to the silymarin treated group.

Serum total protein, also known as total protein, is a biochemical test for measuring the total amount of

protein in serum. Total protein measurements can reflect nutritional status and may be used to screen for and help diagnose kidney disease or liver disease. Serum total protein concentration will reduce if there is any liver dysfunction. In the present study, treatment with 40% ethanol (2 ml/100 g) caused significant reduction in serum total protein ($P<0.001$). Treatment with essential oil (10 mg/kg) and silymarin (100 mg/kg) caused significant increase in the levels of total protein ($P<0.01$), indicating normalization of liver function, but essential oil at the dose rate of 5 mg/kg did not result in any significant elevation in total protein values. Albumin is the major plasma protein and is synthesized exclusively in the liver. Plasma albumin reflects hepatic function. It is one of the standard liver function tests. Albumin synthesis is reduced during hepatic toxicity. Treatment with 40% ethanol (2 ml/100 g) caused significant reduction in serum albumin ($P<0.01$) in the present study. However treatment with essential oil (10 mg/kg) and silymarin caused significant increase in the levels of albumin ($P<0.01$), indicating reversal of hepatic damage, but essential oil at the dose rate of 5 mg/kg did not result in any significant elevation in albumin levels (Table II).

Bilirubin is an endogenous anion derived from

TABLE I: Effect of essential oil from *Etingera fenzlii* on biochemical parameters of ethanol induced toxicity in Wistar rats.

Groups	Design of treatment	AST(U/L)	ALT(U/L)	ALP(U/L)
I	Vehicle control	176.08±18.86***	47.11±6.61***	552.11±122.83***
II	Ethanol (40% v/v, 2 ml/100 g)	276.56±32.75	84.86±11.86	854.61±76.12
III	Ethanol (40% v/v, 2 ml/100 g) + Silymarin (100 mg/kg)	211.31±53.83**	55.16±15.58***	691.91±37.23*
IV	Ethanol (40% v/v, 2 ml/100 g) + EOEF (5 mg/kg)	209.03±11.79**	56.60±12.05***	655.85±123.48**
V	Ethanol (40% v/v, 2 ml/100 g) + EOEF (10 mg/kg)	208.31±10.95**	53.10± 9.56***	658.85±117.59**

Values are Mean±SD, $n=6$ animals per group, EOEF- Essential oil of *Etingera fenzlii*, * $P<0.05$, ** $P<0.01$, *** $P<0.001$ when compared with Group II. (One way analysis and Dunnet test).

TABLE II: Effect of essential oil from *Etingera fenzlii* on nonenzymatic liver function of ethanol induced toxicity in Wistar rats.

Groups	Design of treatment	Total protein (g/dl)	Albumin (g/dl)	Bilirubin (mg/dl)
I	Vehicle control	6.83±0.09***	2.10±0.08**	0.10±0.00**
II	Ethanol (40% v/v, 2 ml/100 g)	5.34±0.44	1.68±0.18	0.38±0.14
III	Ethanol (40% v/v, 2 ml/100 g) + Silymarin (100 mg/kg)	6.66±0.68**	2.06±0.18**	0.18±0.11
IV	Ethanol (40% v/v, 2 ml/100 g) + EOEF (5 mg/kg)	5.76±0.59	1.83±0.22	0.21±0.20
V	Ethanol (40% v/v, 2 ml/100 g) + EOEF (10 mg/kg)	6.60±0.70**	2.10±0.15**	0.16±0.05*

Values are Mean±SD, $n=6$ animals per group, EOEF- Essential oil of *Etingera fenzlii*, * $P<0.05$, ** $P<0.01$, *** $P<0.001$ when compared with Group II. (One way analysis and Dunnet test).

TABLE III: Effect of essential oil from *Etingera fenzlii* on body and liver weight of ethanol induced toxicity in Wistar rats.

Groups	Design of treatment	Initial body weight (g)	Final body weight (g)	Liver weight (g)
I	Vehicle control	133.33±9.83	211.66±13.66	5.17±0.24***
II	Ethanol (40% v/v, 2 ml/100 g)	132.50±9.35	142.50±18.90	2.93±0.17
III	Ethanol (40% v/v, 2 ml/100 g) + Silymarin (100 mg/kg)	132.50±9.35	154.16±7.36	3.763±0.389***
IV	Ethanol (40% v/v, 2 ml/100 g) + EOEF (5 mg/kg)	132.50±9.35	153.33±17.22	3.497±0.263**
V	Ethanol (40% v/v, 2 ml/100 g) + EOEF (10 mg/kg)	132.50±9.35	155.83±13.57	3.70±0.17***

Values are Mean±SD, n=6 animals per group, EOEF- Essential oil of *Etingera fenzlii*, * P<0.05, ** P<0.01, *** P<0.001 when compared with Group II. (One way analysis and Dunnet test).

hemoglobin degradation from the RBC. When the liver function tests are abnormal and the serum bilirubin levels more than 17 µmol/L underlying liver disease is suspected. Serum bilirubin level was increased significantly by the ethanol (2 ml/100 g) treatment (P<0.01) in the present study. However significant reduction in bilirubin (P<0.05) was noted in treatment with essential oil (10 mg/kg) and silymarin. Essential oil at the dose rate of 5 mg/kg did not show any significant decrease in bilirubin. High amount of alcohol showed a lower body and liver weight essentially due to fat mass reduction. In the present study also it was found that ethanol treated (negative control) group showed lesser body and liver weight compared to the normal control group (Table III).

Histopathological studies

Histological architecture of ethanol treated liver sections showed fatty degeneration of hepatocytes with hepatocellular degeneration and areas of necrosis of hepatocytes. Essential oil treatment almost normalised these defects in the histological architecture of the liver resembling that of silymarin treated groups, showing its potent hepatoprotective effects (Fig. 1 A-E). Hepatoprotective effect of essential oil was further confirmed by histopathological studies of the liver, which basically supported the results from the serum assays.

Discussion

The hepatoprotective activity of essential oil was investigated on ethanol induced liver damage in Wistar albino rats, which is a commonly used animal model. Alcohol has been used as a successful

experimental model to evaluate the efficacy of hepatoprotective agents. In general, ethanol produces a constellation of dose related deleterious effects in the liver (11). Both acute and chronic ethanol administration cause enhanced formation of cytokines, especially TNF-alpha by hepatic Kupffer cells, which have a significant role in liver injury (12). Reduced adipose tissue may be the foremost cause of lower body weight. As ethanol can supplement a large part of energy requirement therefore nutritional disorders may occurs (13, 14). Ethanol caused deleterious effects on rats producing oxidative stress in the liver as a result of the generation of superoxide radicals by ethanol metabolism. Elevated levels of serum glutamic oxaloacetic transaminase (SGOT/AST) and serum glutamic pyruvic transaminase (SGPT/ALT) are indications of hepatocellular injury. Silymarin is a known hepatoprotective compound obtained from *Silybum maianum*. It is reported to have a protective effect on plasma membrane of hepatocytes (15). Silymarin appears to be effective in reducing the serum levels and it is indicated the ability of silymarin to preserve the normal functional status of liver. The hepatoprotective effect was further confirmed by histopathological examination of the liver. The histopathological observation basically supported the results from the serum assays.

Ethanol alters many aspects of endocrine function such as all levels of the hypothalamic- pituitary-adrenal axis, gonadal activity and carbohydrate, fat, mineral metabolism (16). Hepatic lipogenesis, peripheral fat mobilization and hepatic uptake of circulating lipids are increased while hepatic uptake of circulating lipids is increased while hepatic lipoprotein release is decreased. The altered NADH/NAD+ ratio impede the function of the tricarboxylic

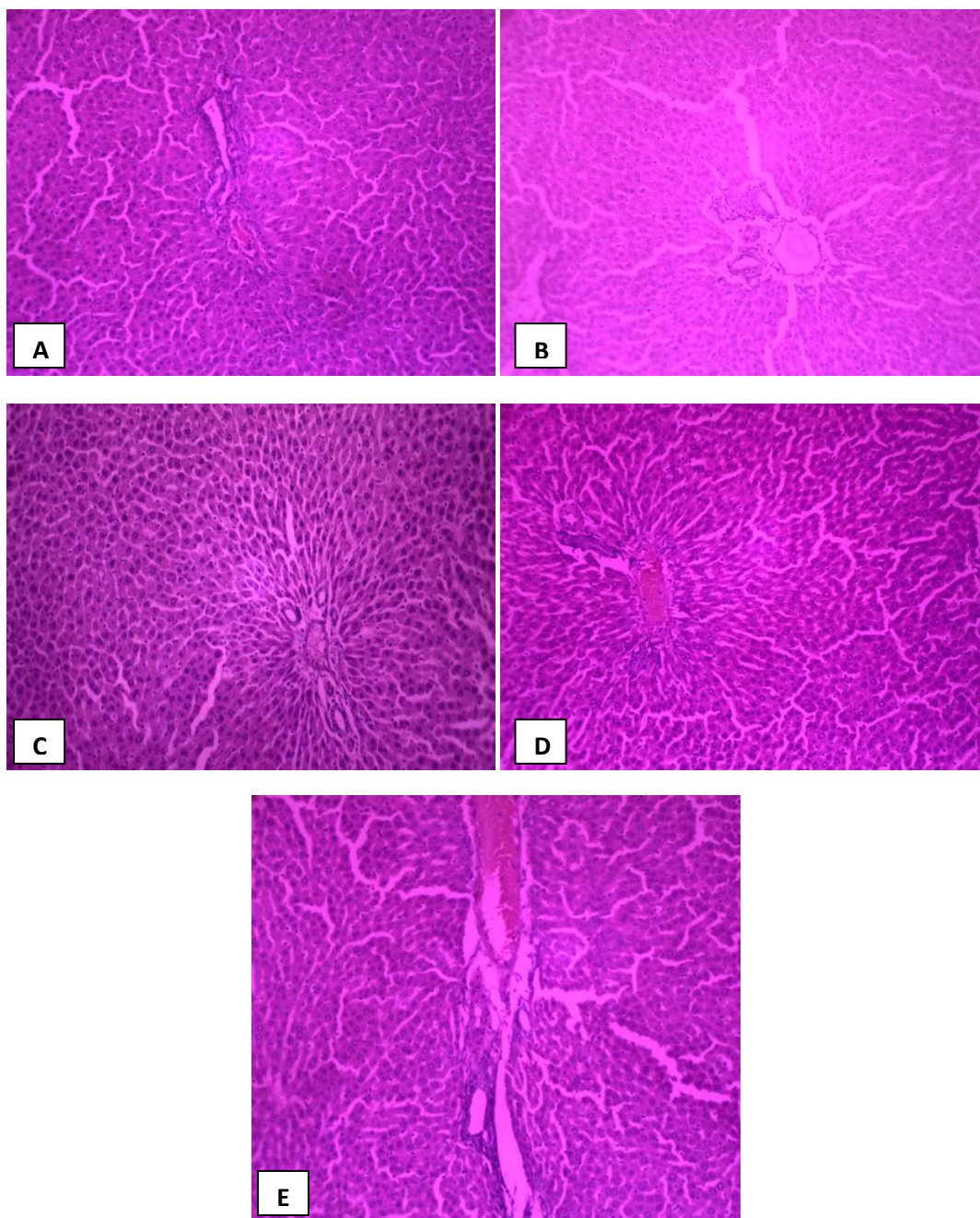


Fig. 1: Effect of EOEF on liver histopathology of ethanol treated Wistar albino rats. Stain: hematoxylin-eosin. (A) Vehicle control group showing normal histology with normal liver architecture; (B) Ethanol treated section of showing sinusoidal congestion, hepatocellular degeneration and areas of necrosis of hepatocytes. (C) Silymarin treated group section of liver tissue shows normal hepatocytes without any fat vacuoles and necrosis. Normal portal triads and hepatic veins. (D) EOEF (5 mg/kg) treated group section of liver tissue shows normal hepatocytes and absence of hepatic necrosis. (E) EOEF (10 mg/kg) treated group section shows normal hepatocytes.

acid cycle and slow fatty acid oxidation. These actions lead to the accumulation of triglycerides in hepatocytes (steatosis) and increase in serum triglycerides (17). Ethanol associated liver disorders include fatty infiltration, alcoholic hepatitis and

fibrosis (18). Serum activities such as ALT and AST are sensitive markers employed in the diagnosis of liver diseases. In the present study serum ALT and AST levels were significantly increased after ethanol injection, suggesting that ethanol induced liver

damage. Ethanol induced hepatotoxicity and nephrotoxicity are evidenced by histopathological damage as well as elevated levels of alanine transaminase (ALT), aspartate transaminase (AST) and alkaline phosphatase (ALP) in liver. The elevated ALT and AST activities might be related to hepatocellular plasma membrane damage because these enzymes originally present in high concentrations in the cytoplasm (19, 20). Ethanol provokes toxic effects through the generation of reactive oxygen species (ROS) and lipid peroxidation in different tissues and cell types. In addition to oxidative stress, ethanol can provoke apoptosis in several cells through the induction of the mitochondrial pathway or death receptor signalling (21, 22). When liver cells are in injury, these enzymes leak into the blood stream and manifest significantly elevated serum levels and the extent of liver damage is in conformity with the elevated serum levels of these enzymes (23). In this study, cellular damage was measured in terms of release of leakage enzymes- AST, ALT and ALP. AST, ALT and bilirubin are the most sensitive tests for diagnosis of liver diseases (24). Treatment with essential oil of *E.fenzlii* decreased the serum levels of ALT and AST towards their respective normal value that is an indication of stabilization of plasma membrane as well as repair of hepatic tissue damage caused by ethanol. On the other hand ALP is an indicator of pathological alteration in biliary flow (25). Ethanol induced elevation of serum ALP is in line with high levels of serum bilirubin. Effective control of ALP and bilirubin levels in essential oil treatment groups points towards an early improvement in the secretory mechanism of hepatocytes. Plasma was obtained for the activities of alkaline phosphatase and alanine aminotransferase as well as for the quantification of the total bilirubin concentration (26). The total protein level will be depressed in hepatotoxic conditions due to defective protein biosynthesis in liver. The ethanol intoxication causes disruption of polyribosomes on endoplasmic

reticulum and thereby reducing the protein synthesis. The essential oil treatment restored the protein synthesis by protecting the polyribosomes. Oxidative stress is responsible for more than 100 human diseases (27) and liver diseases remain one of the serious health problems worldwide (28).

Conclusion

In conclusion, the result of this study demonstrates that essential oil of *E.fenzlii* has potent hepatoprotective action upon ethanol induced hepatic damage in rats. Histopathological observation of the liver tissue had directly supported this conclusion. Scientific rationale for the traditional use of the plant and also points out that *E.fenzlii* warrants future detailed investigation as a promising hepatoprotective agent.

Acknowledgements

We thank the Director, Jawaharlal Nehru Tropical Botanic Garden and Research Institute, Palode, Thiruvananthapuram, for laboratory facilities and encouragement. We also thank Dr Pandae, Deputy Director, Botanical Survey of India, Andaman and Nicobar Circle, Port Blair, Dr Viswakannan, Conservator of Forests and Mr Sajan Paul, Deputy Conservator of Forest, Forest Department, Andaman-Nicobar Administration for their efforts to render maximum facilities for plant exploration in Great Nicobar Island. We also express sincere thanks to Dr. Sam P Mathew for collecting plants from Andaman Nicobar Islands.

Financial support and sponsorship:

The authors are grateful to Kerala State Council for Science, Technology & Environment, Government of Kerala and University of Kerala for financial support.

References

1. Mathew P Sam, Radha RK, Krishan PN, Seeni S. Phytogeography of the Andaman- Nicobar Islands with special reference to *Hornstedtia fenzlii* (Kurz) K.Schum. *Curr Sci* 2010; 98: 905-907.
2. Anju Sudhakaran, Radha RK. Evaluation of Acute and Dermal Toxicity of Essential Oil of *Etlingera Fenzlii* (Kurz) K. Schum: An *In Vivo* Study. *Int J Pharm Pharm Sci* 2016; 8(7): 69-72.

3. Garg SC, Banerjee A. Insect and pest control activity of essential oils. *Indian Perfumer* 1997; 41: 73–84.
4. Chang ST, Cheng SS. Antitermitic activity of leaf essential oils and components from *Cinnamomum osmopheum*. *J Agr Food Chem* 2002; 50: 1389–1392.
5. Sun B, Karin M. NF- κ B signaling, liver disease and hepatoprotective agents. *Oncogene* 2008; 27: 6228–6244.
6. Arias IM, Alter HJ, Boyer JL, Cohen DE, Fausto N, Wolkoff AW. The liver: biology and pathobiology, *Fifth ed.* John Wiley & Sons Ltd; 2010.
7. Muhammad HR, Mahmood T, Salim T, Afzal N, Nasir A, Iqbal J. Effect of silymarin and serum levels of ALT and GGT in ethanol induced hepatotoxicity in albino rats. *J Ayub Med Coll Abbottabad* 2009; 21(4): 73–75.
8. Vetriselvan S, Rajamanikkam V, Parimala Devi, Subasini Arun G. Comparative evaluation of hepatoprotective activity of *Andrographis paniculata* and silymarin in ethanol induced hepatotoxicity in albino wistar rats. *Der Pharm Lett* 2010; 2(6): 52–59.
9. Subramoniam A, Pushpangadan P. Development of phytomedicine for liver diseases. *Indian J Pharmacol* 1999; 31: 166–175.
10. Bahar A, Tanveer A, Manoj V, Shah A K (2002) Hepatoprotective activity of two plants belonging to the apiaceae and the euphorbiaceae family. *Journal of Ethnopharmacology* 2002; 79: 313–316.
11. Leo MA, Arai M. Hepatotoxicity of vitamin A and ethanol in the rat. *Gastroenterology* 1982; 82: 194–205.
12. Zhou Z, Wang L, Song Z, Lambert JC, McClain CJ, Kang YJ. A critical involvement of oxidative stress in acute alcohol-induced hepatic TNF- α production. *American Journal of Pathology* 2003; 163: 1137–1146.
13. Dinu V, Zamfir O. Oxidative stress in ethanol intoxicated rats. *Rev Roum Physiol* 1991; 28(2): 63–67.
14. Chandra R, Aneja R, Rewal C, Konduri R, Dass SK, Agarwal S. An opium alkaloid-*Papaverine* ameliorates ethanol-induced hepatotoxicity: diminution of oxidative stress. *Ind J Clin Biochem* 2000; 15(2): 155–160.
15. Ramellini G, Meldolesi J. Liver protection by silymarin *In vitro* effect on dissociated rat hepatocytes *Arzneim Forsch. Drug Research* 1976; 26: 69–73.
16. Adler RA. Clinically important effects of alcohol on endocrine function. *J Clin Endocrinol Metab* 1992; 74: 957–960.
17. Liber CS. Hepatic and metabolic effects of ethanol: pathogenesis and prevention. *Ann Med* 1994; 26: 325–330.
18. Liber CS. Medical disorders of alcoholism. *N Engl J Med* 1995; 333: 1058–1065.
19. Gan D, Ma LP, Jiang CX, Wang MC, Zeng XX. Medium optimization and potential hepatoprotective effect of mycelial polysaccharides from *Pholiota dinghuensis* Bi against carbon tetrachloride-induced acute liver injury in mice. *Food Chem Toxicol* 2012; 50: 2681–2688.
20. Nada SA, Omara EA, Abdel-Salam OM, Zahran HG. Mushroom insoluble polysaccharides prevent carbon tetrachloride -induced hepatotoxicity in rat. *Food Chem Toxicol* 2010; 48: 3184–3188.
21. Yang HY, Lin HS, Chao JC, Chien YW, Peng HC, Chen JR. Effects of soy protein on alcoholic liver disease in rats undergoing ethanol withdrawal. *J Nut Biochem* 2012; 23: 679–684.
22. Darwish HA, Abd Raboh NR, Mahdy A. Camel's milk alleviates alcohol induced liver injury in rats. *Food Chem Toxicol* 2012; 50: 1377–1383.
23. Drotman RB, Lawhorn GT. Serum enzymes are indicators of chemical induced liver damage. *Drug and Chemical Toxicology I* 1978; 163–171.
24. Mahendale HM, Gupta PK, Shalunkhe DK. Hepatic Toxicity, vol. 1. New Delhi: Metropolitan Books; 225: 1985.
25. Ploa GL, Hewitt WR. In: Wallace Hyes, A. Principle and Methods of Toxicology. New York: Raven Press; 1989. p. 399.
26. Fernandez Martinez E, Perez- Alvarez V, Tsutsumi V, Shibayama M, Muriel P. Chronic bile duct obstruction induces changes in plasma and hepatic levels of cytokines and nitric oxide in the rat. *Exp Toxicol Pathol* 58; 49–58.
27. Kosecik M, Erel O, Sevinc E, Selek S. Increased oxidative stress in children exposed to passive smoking. *International Journal of Cardiology* 2005; 100: 61–64.
28. Huang B, Ban XQ, He JS, Zeng H, Zhang P, Wang YW. Hepatoprotective and antioxidant effects of the methanolic extract from *Halenia elliptica*. *Journal of Ethnopharmacology* 2010; 131: 276–281.